

Familial Tumoral Calcinosis with GALNT3 Mutation: Radiographic Sedimentation Sign and Chicken-Wire Pattern

Bhanu Teja Nalluri^{1*}, Rohit Meka¹, Neelaveni Kudugunti², Vijay Pavan Kumar D³ and Rakesh Kumar Sahay²

¹Resident, Department of Endocrinology, Osmania Medical College, Hyderabad, India

²Professor, Department of Endocrinology, Osmania Medical College, Hyderabad, India

³Associate Professor, Department of Radiology, Osmania Medical College, Hyderabad, India

Abstract

A 25-year-old woman presented with progressive, painless periarticular soft-tissue swellings around the right shoulder for 8 years.

Keywords: Genetic testing, tumoral calcinosis, GALNT3 Mutation.

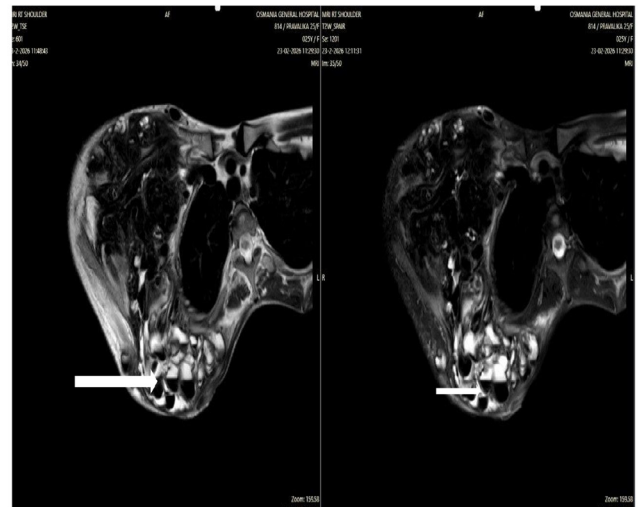
Clinical Image

A 25-year-old woman presented with progressive, painless periarticular soft-tissue swellings around the right shoulder for 8 years. Examination revealed firm, non-tender lobulated masses without overlying skin changes or joint restriction. Serum phosphorus was elevated with normal calcium and inappropriately elevated tubular reabsorption of phosphate. Genetic testing confirmed a homozygous pathogenic variant in GALNT3.

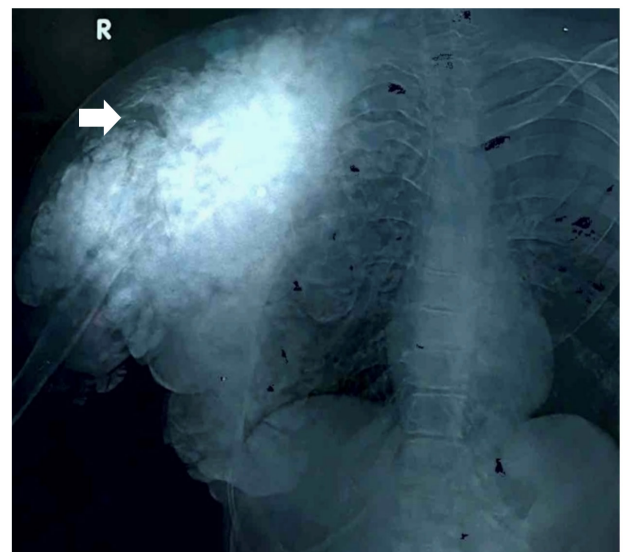
Anteroposterior radiograph of the right shoulder (Panel A) demonstrates a large periarticular calcified mass. The sedimentation sign (white arrow) - a horizontal fluid-calcium level within lobulated cystic spaces - reflects dependent layering of calcium hydroxyapatite particles, a pathognomonic feature of tumoral calcinosis. Thin curvilinear septations demarcating adjacent calcific lobules produce the chicken-wire (cobblestone) pattern (arrowhead), representing fibrous walls encasing calcium-laden compartments. Axial T2-weighted MRI along with X-ray shoulder confirms multiloculated heterogeneous periarticular masses with hypointense calcific septations and hyperintense fluid foci, with no osseous invasion.

These imaging hallmarks, when combined with hyperphosphatemia and GALNT3 mutation, establish the diagnosis of Familial Tumoral Calcinosis.

Panel A: Axial T2-weighted MRI of right shoulder the sedimentation sign (white arrow) - a horizontal fluid-calcium level within lobulated cystic spaces — reflects dependent layering of calcium hydroxyapatite particles, a pathognomonic feature of tumoral calcinosis.



Panel B: X-ray of right shoulder (anteroposterior view) thin curvilinear septations demarcating adjacent calcific lobules produce the chicken-wire (cobblestone) pattern (arrowhead).



*Corresponding Author: *Bhanu Teja Nalluri, Resident, Department of Endocrinology, Osmania Medical College, Hyderabad, India

Citation: Bhanu Teja Nalluri*, Familial Tumoral Calcinosis with GALNT3 Mutation: Radiographic Sedimentation Sign and Chicken-Wire Pattern. Jour of Clin & Med Case Rep, Imag 2026; 6(1): 1201.

References

1. [Hug I, Guncaga J \(1974\) Tumoral calcinosis with sedimentation sign. *Br J Radiol* 47\(554\):734-736.](#)
2. Olsen KM, Chew FS (1996) Tumoral calcinosis: radiologic-pathologic correlation. *Radiographics*. 16(3):573-580.